



PATIENT

Lua Howell

SPECIES

Canine

BREED

Min. Schnauzer

SEX

FS

AGE

11 y

WEIGHT

10.2 lb

INTERPRETED BY

Keith Blass, DVM, MS,
DACVIM (Cardiology)

IMAGING PERFORMED BY

Dr. Ashley Whitesell

HOSPITAL NAME

Dickson AC

REFERRING VET

Dr. Rowan

INVOICE

DATE

5/20/26

PRESENTING CLINICAL SIGNS

Grade IV/VI murmur. Grey zone BNP. Cough.

ECHOCARDIOGRAPHIC FINDINGS

2D, M-mode, and Doppler study.

There is mild to moderate left atrial dilation. The mitral valve leaflets are thickened and exhibit systolic prolapse. There is Doppler evidence of mitral regurgitation present. There is mild to moderate left ventricular dilation. Left ventricular systolic function is hyperdynamic. The aorta and aortic valve are normal. Right atrial and right ventricular dimensions are normal. The tricuspid valve is normal. The pulmonary artery and pulmonic valve are normal. No shunting lesions are visualized. No heartworms are visualized. No pericardial effusion or cardiac masses are seen.

ECG during echo: Sinus rhythm

LA - 28.6 mm
LVIDd - 29.0 mm
LVIDs - 14.7 mm
FS - 49.3%
RA - 14.5 mm
LVOT - 1.71 m/s
RVOT - 0.86 m/s

ASSESSMENT/RECOMMENDATIONS

Degenerative mitral valve disease - stage B2

This examination demonstrates regurgitation of blood across Lua's mitral valve resulting from degenerative valve disease. Secondary to her regurgitation, Lua has mild to moderate dilation of both her left atrium and left ventricle, though her left ventricular systolic function is well-preserved. Given the absence of more advanced left heart chamber enlargement, it's unlikely that mainstem bronchial compression is contributing to Lua's cough, however, she is at mildly to moderately increased risk for the development of exercise intolerance, syncope, and/or labored breathing, therefore, careful monitoring for these is recommended.

Thoracic radiographs may be warranted to further evaluate Lua's cough.

I recommend starting Lua on pimobendan (1.25 mg BID), as this medication should help to slow the progression of her mitral valve disease.

A recheck echocardiogram is recommended in 6-9 months.



PATIENT

Lua Howell

SPECIES

Canine

BREED

Min. Schnauzer

SEX

FS

AGE

11 y

WEIGHT

10.2 lb

INTERPRETED BY

Keith Blass, DVM, MS,
DACVIM (Cardiology)

IMAGING PERFORMED BY

Dr. Ashley Whitesell

HOSPITAL NAME

Dickson AC

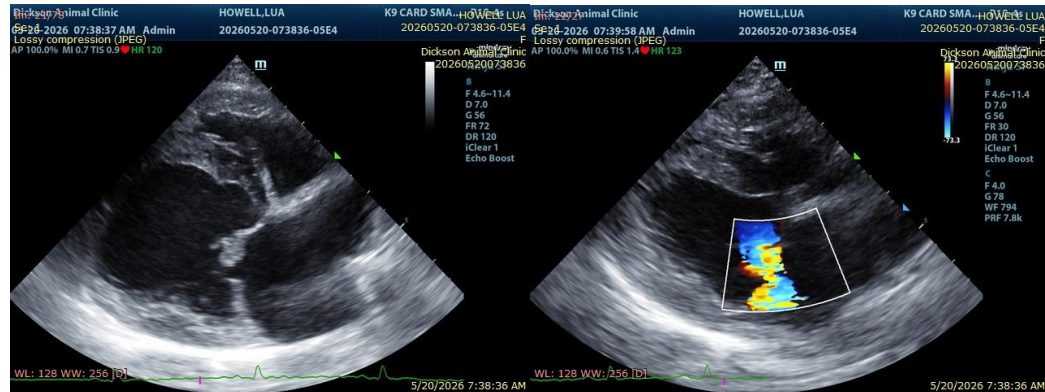
REFERRING VET

Dr. Rowan

INVOICE

DATE

5/20/26



The information and recommendations provided are based on the images presented by the referring veterinarian/sonographer. No evaluation can be communicated regarding pathology that was not visible in the image/video clips provided.

Thank you for this referral. If the clinical or image interpretation does not parallel your findings or if I can be of any further assistance please contact me.

Keith Blass, DVM, MS, DACVIM (Cardiology) info@SonoPath.com